

Age, Gender and Pattern Distribution of Impacted Third Molar among the Patients Attending Teaching Hospital of Lahore

RABIA ANJUM, NADIA NASEEM, A.H NAGI

ABSTRACT

Aim: To determine the distribution of age, gender and pattern of impacted third molar.

Method: This descriptive study was conducted at department of Morbid Anatomy and Histopathology, University of Health Sciences Lahore Pakistan. Patients complaining of impacted teeth along with two diagnostic X rays, age, gender, type of impaction and associated pathology were recorded.

Results: Total of 100 patients was included in this study. Out of these males were predominant. The mean age was found to be 27.58 ± 6.45 years. Mandibular impactions were most common (96%). Regarding angulation, mesioangular impaction (58%) were frequently found and pain was the commonest symptom (80%) associated with impacted teeth.

Conclusion: Impacted third molar is predominantly seen in mandible with the males being most commonly involved. Mesioangular impactions were the most common.

Keywords: Impacted third molar, age, gender

INTRODUCTION

Teeth that are permitted from eruption by an objective within the path of eruption are known as impacted teeth¹.

Lack of space, malposition or other hindrances is responsible for the tooth being impacted². The mean age is being 17 years. The wide age series as well as positional changes are mainly due to nature of the diet, the intensity of the use of the masticatory apparatus, race differences and genetic background². Usually, there is no gender dominance³.

Winters (1926) classification is the most common system. According to this system impacted third molars can be divided as mesioangular, distoangular, horizontal and vertical⁴.

The aetiology of impactions can be local and systemic. Tooth germs malposition, lengthened deciduous tooth retention, early loss of primary teeth, arch length deficiency, supernumerary teeth, odontogenic tumours, etc are the local factors. Systemic causes can be pre or postnatal².

The common symptoms related with impacted third molar are pain, red and swollen gums, swelling around the jaw, halitosis, and headache⁵.

Pericoronitis, unrestorable caries, internal or external resorption of tooth or adjacent teeth, and any follicular disease including cyst / tumour are the suggested indications for the removal of impacted third molar⁶.

*Department of Morbid Anatomy & Histopathology,
University of Health Sciences, Lahore,
Correspondence to Dr. Rabia Anjum, 167 Sikander Block,
Lane 5 Allama Iqbal Town Lahore, Email:
dr.rabiaanjum@gmail.com Cell: +923234460006*

SUBJECT AND METHODS

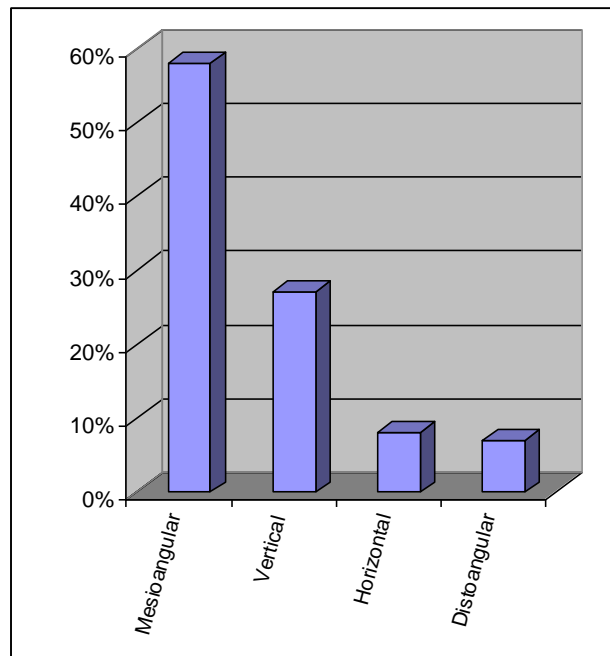
This descriptive study was conducted in the Department of Morbid Anatomy and Histopathology/Oral Pathology at University of Health Sciences, Lahore Pakistan. A total of 100 patients were taken from the Oral and Maxillofacial Surgery Department of de' Montmorency College of Dentistry, Lahore Pakistan in a duration from April to July 2013. These patients reported with pain, limited mouth opening, halitosis, swelling or for any other dental procedures and each patient in the research signed an informed consent form.

RESULTS

Among 100 patients the mean age was 27.58 ± 6.45 (Range 18 to 53) years. There were 55 males and 45 females with male to female ratio of 1.27:1.

Among 100 of cases 51 were from right and 45 from the left side of mandible while 3 cases were from left side and 1 from right side of maxilla. There were 43% completely bony and 5% partially bony impacted in 100 cases. Among 100 patients 80(80%) were presented with variable nature of pain that was throbbing, intermittent and continues radiating up to the ear and down in the neck sometimes awaking the patient whole night. Out of 100 patients 25% patients complained of limited mouth opening with or without pain. Swelling and redness of soft tissues (gingival) around the eruption site of impacted third molar was seen in 77% patients. In 74% patients clinically diagnosis associated with impacted third molar was made as pericoronitis. On radiography, following findings were observed.

Fig 1: This graph shows the distribution of angulation of impacted third molars. Note that mesioangular was the commonest (58%) impaction observed.



DISCUSSION

The impacted third molar is a common problem in our population that may result in a health risk to patients. The mean age of patients was 27.58 ± 6.45 years and age range was 18 to 53 years in present study. In another study done by Kaya mean age reported was 24.71 ± 6.32 (16-45) years and 26.59 ± 9.95 (16-59) years for women and men respectively⁷. These findings are almost consistent with the results reported in present study. In another study, age range was reported from 20 to 50 years that is again consistent with the present study⁸. In contrast to the present study, higher proportions of patients (13%) older than 40 years were reported in a study by Ishfaq M. This could be due to lack of oral health awareness leading to delay in treatment in these patients⁹. This age difference can be due to various reasons like rational differences, or late report by the patients at clinics or hospitals. As in our society third molar and its related pain is usually ignored or tolerated by the patients.

Regarding gender, 56% of the patients were male and 44% were females. In a similar study by Tegginamani and Prasad 58 % of the patients were males and 42% females thus indicating the male predominance¹⁰ which is consistent with the results reported in the present study. The male predominance (55% males and 44% females) was also seen in another study done by Monica⁸

.Similarly, a study in the U.S.A reported that majority of the patients were males (57%)¹¹ whereas 74% females and 26% males have been reported in the study done by Khorasani and Samiezadeh¹². This gender difference can be due to certain geographical, environmental and social factors.

Venu Gopal conducted a comparative study on impacted third molar in South India which showed greater tendency of impacted third molar towards the mandible, which also supports our findings¹³. Hashemipour study on Iranian population analysis also showed 1.9 times more probability of impactions to occur in the mandibular than maxillary arch¹⁴. This can be due to various reasons as lacking of space, insufficient anteroposterior dimension, delayed mineralization and early physical maturation of third molar¹⁵.

Regarding the laterality of impacted third molar, they were predominantly found on the right side of mandible 18 (40.9%) as compared to the left side 14(31.8%) in a study done by Nasreen Amanat, in Karachi¹⁶, Pakistan that is in accordance with our results. A Similar study reported higher frequency (15.9% vs 11.3%) on the right side than on the left side in maxilla that is in contrast to our results¹⁷.

As the results showed pain, swelling and pericoronitis were frequent findings which are consistent with the findings observed in a study done by Doğan¹⁸. Another study by Suneel Kumar Punjabi also reported pain a most common finding associated with impacted third molar followed by pericoronitis¹⁹. Various other studies done in Malaysia, India and Pakistan reported pericoronitis the most common finding^{9,20}.

In the present study there were 6%, 9%, 26% and 59% distoangular, horizontal, vertical and mesioangular impactions respectively thus indicating vertical and mesioangular impactions were most common. A similar study reported the vertical and mesioangular impactions were most common which is consistent with the present study¹². In another study by Patil again vertical and mesioangular impactions were most common²¹. Our findings are also in accordance with the previous reports from Pakistan, USA, China, and Malaysia, where the mesioangular impactions were most common^{9,11,17}. However, a study among Jordanians reported the vertical impactions were most common (61.4%) and mesioangular were only 18%²². The possible reason for high incidence of mesioangular impaction can be due to differential growth present between mesial and distal roots of third molar. Depending on the proportion of the root development, mesial root underdevelopment may lead to mesioangular impaction, and overdevelopment of the same root may result in distoangular impaction. Normal

rotations of third molars are expected to occur to mesioangular or vertical from horizontal and mesioangular respectively. If the rotation from mesioangular to vertical position fails then it leads to mesioangular impactions²³.

CONCLUSION

Within the limitation of the study, it can be concluded that impacted third is a common problem. Most common age involved was third decade. There was male predominance in our study. Impacted third molars were most common in mandible than maxilla with the right side being most commonly involved. Pain and pericoronitis were the common symptoms associated with impacted third molars. Mesioangular impactions were frequently found followed by Vertical impactions. However further study can be carried out on large sample size.

Acknowledgement: The authors acknowledge the encouragement extended by the Vice Chancellor of UHS Lahore Pakistan. Also, to Mr. Waqas Latif, the biostatician, Miss Sadia Maqbool and Mr. Sameer Anjum, the laboratory staff of Oral Pathology Department of University of Health Sciences Lahore, Pakistan.

REFERENCES

- Farman, AG. Tooth Eruption and Dental Impactions. Panoramic Imaging News;2004.4 (2): 1-9.
- Qirreish,EJ.Radiographic profile of symptomatic impacted mandibular third molars in the Western Cape, South Africa. Masters degree dissertation. Western Cape: University of Western Cape. 2005.
- Hattab, FN, Rawashdeh ,MA and Fahmy ,MS. Impaction Status of Third Molars in Jordanian Students. Oral Surg. Oral Med. Oral Pathol. Oral Radiol and Endod. 1995; 82: 10-7.
- Obimakinde,OS. Impacted mandibular third molar surgery; an overview. A publication by the dentoscope editorial Board .2009;16:22-24.
- Marciani, RD. Third molar removal: An overview of indications, imaging, evaluation, and assessment of risk. Oral Maxillofac. Surg .Clin. North Am.2007;19:1.
- Mercier, P and Precious, D. Risks and Benefits of Removal of Impacted Third Molars. A Critical Review of the Literature. J. Oral Maxillofac.Surg.1992;21:17-27.
- Simşek, KG ,Özbek, E., Kalkan,Y, Yapici, G ,Dayi, E and Demirci,T. Soft tissue pathosis associated with asymptomatic impacted lower third molars. Med. Oral Patol. Oral Cir. Bucal. 2011; 16 (7):e929-36.
- Yadav, M , Meghana, SM ,Deshmukh, A and Godge, P. The wisdom behind third molar extraction: A clinicopathologic study. International Journal of Oral and Maxillofacial Pathology.2011; 2(3):7-12.
- Ishfaq M, Wahid A, Rahim AU, Munim A. Patterns and presentations of impacted mandibular third molars subjected to removal at Khyber College of Dentistry Peshawar. Pak Oral Dent J. 2006; 26: 221-26.
- Tegginamani, AS and Prasad, R. Histopathologic evaluation of follicular tissues associated with impacted lower third molars.J. Oral Maxillofac. Pathol.2013;17:414.
- ypes, frequencies and risk factors for complications after third molar extraction. J Oral Maxillofac Surg .2003; 61: 1379-89.
- Khorasani,M and Samiezadeh,F.Histopathologic Evaluation of Follicular Tissues Associated with Impacted Third Molars. J. Dent.2008; 5: 2.
- Jaffar RO, Tin-Oo. Impacted mandibular third molars among patients attending Hospital Universiti Sains Malaysia. Archives of Orofacial Sciences. 2009; 4: 7-12.
- Dwellers in the Age Group of 22-30 years in South India: A Comparative Study. J Maxillofac Oral Surg. 2012 Sep; 11(3): 271-5.
- Hashemipour MA, Tahmasbi AM, Fahimi HF. Incidence of impacted mandibular and maxillary third molars:a radiographic study in a Southeast Iran population. Med Oral Patol Oral Cir Bucal. 2013 Jan 1; 18(1): e140-5.
- Quek SL, Tay CK, Tay KH, Toh SL, Lim KC. Pattern of third molar impaction in a Singapore Chinese population; a retrospective radiographic survey. Int J Oral Maxillofac Surg .2003; 32: 548-52.
- Amanat,N, Mirza,D, Rizvi KF. Pattern of Third Molar Impaction:Frequency and Types Among Patients Attending Urban Teaching Hospital of Karachi. Pakistan Oral & Dental Journal.2014; 34(1):34_37.
- Doğan, N, Orhan, K, Günaydin, Y, Köymen, R, Okçu, K and Uçok, O. Unerupted mandibular third molars: symptoms, associated pathologies, and indications for removal in a Turkish population. Quintessence. Int. 2007; 38(8):e497-505.
- Punjabi, SK, Khoso, NA, Butt, AM and Channar, KA. Third Molar Impaction: Evaluation of the Symptoms and Pattern of Impaction of Mandibular Third Molar Teeth. JLUMHS.2013; 12(01): 26.
- Patil, S. Prevalence and type of pathological conditions associated with unerupted and retained third molars in the Western Indian population. *Journal of Cranio-Maxillary Diseases*.2013; 2(1); 10.
- Bataineh AB, Albashaireh ZS, Hazza'a AM. The surgical removal of mandibular third molars: a study in decision making. Quintessence Int 2002; 33: 613-17.
- Gregory, MN and Larry ,JP. Impacted Teeth. In: Michael, M, Ghali ,GE, Peter, EL, Peter,DW, editors. *Peterson's Principles of Oral and Maxillofacial Surgery*. 2nd ed. 2004.Vol. 1 Pp:139–40.